

64-19

**The Recognition of Strictly Posterior
Myocardial Infarction by Conventional
Scalar Electrocardiography**

By JOSEPH K. PERLOFF, M.D.

The Recognition of Strictly Posterior Myocardial Infarction by Conventional Scalar Electrocardiography

By JOSEPH K. PERLOFF, M.D.

ELECTROCARDIOGRAPHIC terminology commonly refers to inferior or diaphragmatic infarction as "posterior."¹⁻⁵ Strictly posterior infarction as a separate entity (fig. 1a) is generally not mentioned.¹⁻⁶ Inclusion of this category permits identification of five individual locations of infarction:⁷ diaphragmatic, lateral, apical, strictly anterior, and strictly posterior.

Myocardial infarction characteristically produces Q waves of abnormal duration in one or more of the 12 standard electrocardiographic leads.^{1,2} These Q waves are written because the initial portion of the QRS is directed away from the area of inert myocardium. If this inert area is electrically posterior (fig. 1a), the initial forces will be directed anteriorly (fig. 1b) (perpendicular to the frontal plane) and no abnormal Q waves will appear in either limb or chest leads.^{8,9} Because of this absence of pathologic Q waves, strictly posterior infarction is one of the most commonly overlooked electrocardiographic abnormalities. Textbooks of electrocardiography, with few exceptions,^{7,9} contain little or no reference to this category.¹⁻⁶ Although some authors have commented upon individual changes that might occur in right precordial leads,^{8,10-15} others have stated that diagnostic signs do not appear in the electrocardiogram as a rule.¹⁶⁻¹⁸ On the other hand, the vectorcardiographic recognition of strictly posterior infarction is generally ac-

cepted.^{9,11,13,15-20} This study was undertaken in order to determine whether the diagnosis of strictly posterior infarction could be established by conventional scalar electrocardiography.

Materials and Methods

Twenty cases were studied, 15 male and five female, with an average age of 55 years and a range of 29 to 80 years (table 1). In 16 cases the diagnoses were based on orthogonal vectorcardiograms and electrocardiograms with use of Schmitt's corrected SVEC III leads. Narrow ranges of normal have been established with this corrected lead system, and quantitative data on the normal orthogonal vectorcardiogram and electrocardiogram are available.²¹ The following information was utilized:²¹ (1) R/S ratio in lead Z—range 0.10 to 1.32, (2) R duration in lead Z—range 0.022 to 0.054 second, mean and one standard deviation 0.038 ± 0.008 second. These data permit accurate detection of an abnormal anterior shift in QRS. In four cases verification of the diagnosis of strictly posterior infarction was based on autopsy evidence. These patients died before vectorcardiograms could be obtained. Proof rests on the validity of attempting to relate the gross anatomic site of infarction to the clinical electrocardiogram. It is recognized that the anatomic names given to the areas of infarction properly relate to the location of altered electrical activity transmitted to the body surface and do not necessarily indicate the region of the heart that has been infarcted. Nevertheless, in each of the four postmortem specimens the left ventricle was infarcted immediately below the atrioventricular sulcus adjacent to the interventricular septum (fig. 7), a location consistent with the pathologic-electrocardiographic correlations of others.^{10,12} This dorsal or infra-atrial portion of left ventricle represents an area that is most likely to be oriented posteriorly in the living subject. Loss of electrical forces in this region offers a reasonable explanation for an anterior shift in the QRS. It is further recognized that the degree of inferior or lateral extension necessary to produce associated diaphragmatic or lateral infarction is basically an

From the Department of Medicine, Georgetown University School of Medicine, Division of Cardiology, Georgetown University Hospital, Washington, D. C.

Supported by a Federal Aviation Agency Grant FAA-2050 and by a United States Public Health Service Research Career Program Award No. 5-K3-He-14,009-03 and Grant HE-08390.

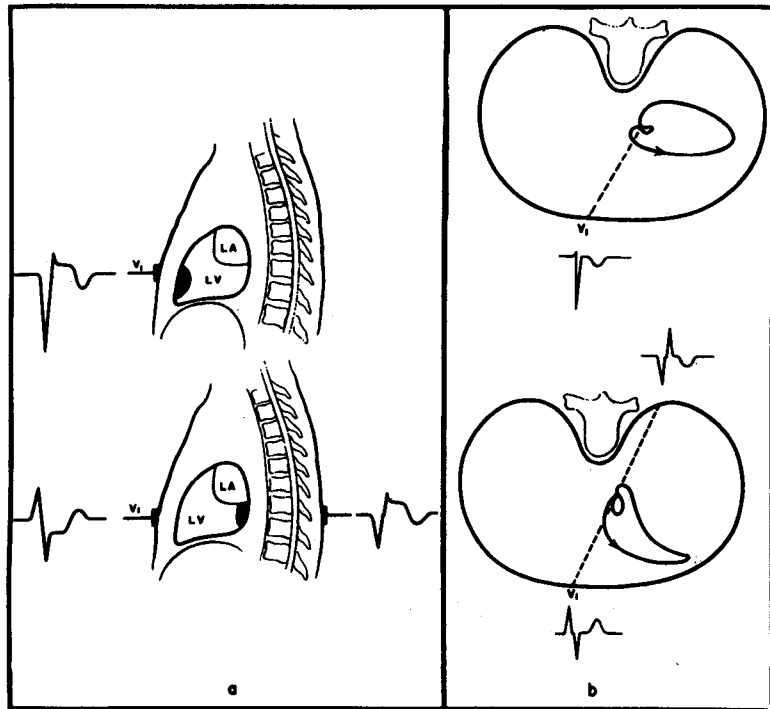


Figure 1

a, Upper. Schematic illustration of strictly anterior infarction producing a Q wave, ST-segment elevation, and T-wave inversion in lead V₁. Lower. Schematic illustration of strictly posterior infarction producing a tall, broad R wave, ST-segment depression, and upright T wave in lead V₁. The familiar "infarct pattern" (Q wave, ST-segment elevation, and T-wave inversion) is recorded posteriorly. b, Upper. Schematic illustration of a normal horizontal plane vectorcardiogram with lead V₁. b, Lower. Schematic illustration of a horizontal plane vectorcardiogram in strictly posterior infarction with lead V₁ and a diametrically opposite posterior lead.

electrocardiographic or vectorcardiographic inference and cannot be accurately determined anatomically.

Three patients had symptoms and serum enzyme evidence of acute infarction, eight had histories of prior infarction, and eight had typical histories of angina or coronary insufficiency. One patient, a 29-year-old man, had received a severe blow in the precordium while boxing 1 year prior to this study. The posterior left ventricular infarct in this case was believed to have been caused by the "contrecoup" effect of the anterior blow. Twelve-lead scalar electrocardiograms were available before and after infarction in three instances. Multiple electrocardiograms (between three and five) were obtained in 12 additional patients. In 10 subjects extra chest leads were taken with the electrodes placed as illustrated in figure 2. Flat electrodes permitted these tracings to be recorded with the patient in the same supine position used when the 12 conventional leads were taken.

The area of infarction was considered to be strictly posterior in 11 patients, postero-diaphragmatic in six, postero-lateral in two, and postero-lateral-diaphragmatic in one. None of the patients had clinical evidence of right ventricular hypertrophy, pulmonary embolism, or chronic lung disease.

Control electrocardiograms were studied as follows. Three observers independently reviewed 250 adult electrocardiograms indexed as "within normal limits." One hundred of these tracings interpreted as normal by all three observers were used for analysis of the duration of the R wave, the R/S ratio, the incidence of slurring of the R or S waves, and the frequency of upright T waves in leads V₁ and V₂ and for analysis of the mean frontal plane QRS electrical axis. There was no clinical evidence of heart disease in this group.

Selected electrocardiograms were also examined in five other categories in which lead V₁ might manifest initial R waves of 0.04-second

Table 1

Clinical Data on the Twenty Patients

Case	Age	Sex		History		VCG	ECG		Acute	Old	Type of Infarct *		PLD	Aneur.
		Male	Female	Ang. cor.	Trauma		Autopsy	Pre and post infarct			One	More		
1	38	M		+		+		+		+				
2	80	M	F	+				+		+				+
3	65	M	F	+		+			+				+	
4	50	M	F	+		+		+		+				
5	61	M		+	+	+		+		+				
6	53	M	F	+		+		+		+				
7	62	M		+		+		+		+				
8	54	M		+		+		+		+				
9	58	M		+	+	+			+	+				
10	62	M		+	+	+		+	+	+				
11	49	M	F	+		+			+	+				
12	57	M		+		+		+		+				
13	40	M		+	+	+		+		+				
14	54	M		+		+		+		+				
15	55	M		+		+		+		+				
16	29	M		+		+		+		+				
17	52	M		+		+		+		+				
18	74	M	F	+	+	+			+	+				
19	62	M		+		+		+		+				
20	50	M		+		+		+		+				
Totals	55	15	5	11	8	1	4	16	4	17	11	2	6	1

* SP, strictly posterior; PL, postero-lateral; PD, postero-lateral-diaphragmatic; PLD, postero-lateral-diaphragmatic; Aneur., posterior aneurysm.

or R/S ratios of one or over. These categories included some normal children, some cases of complete right bundle-branch block, the Wolff-Parkinson-White syndrome with anteriorly directed delta wave, right ventricular hypertrophy, and some normal adults.

Results

The data in the infarct group are summarized in table 2.

In all cases studied with extra chest leads (table 2) the posterior Q area extended well

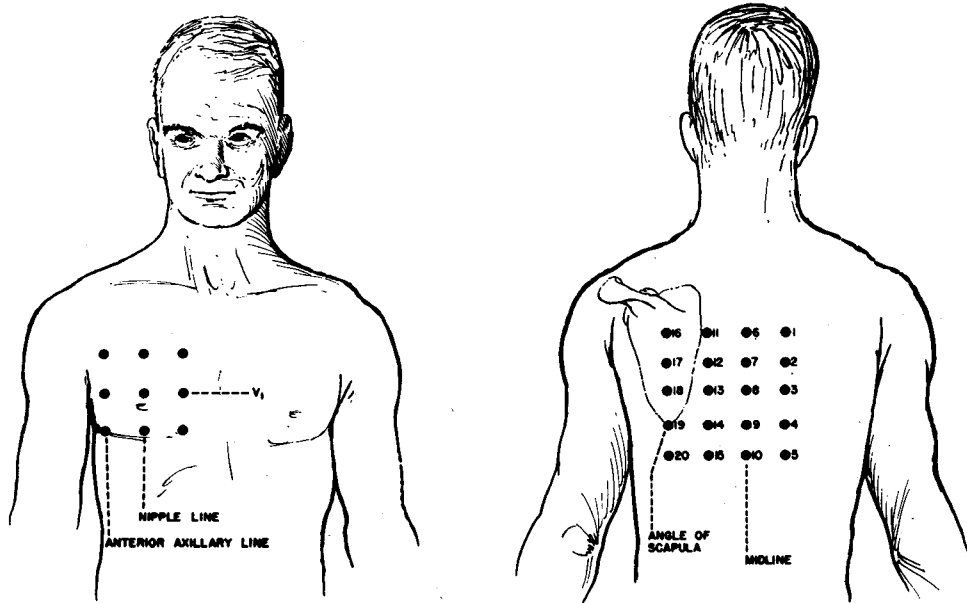


Figure 2

Extra chest leads.

Table 2

Electrocardiographic Data in the Infarct Group

	No cases	Per cent cases
0.04-sec. R V ₁	15/20	75
0.04-sec. R V ₂	20/20	100
0.04-sec. R in rt. ant. chest leads	9/10	90
0.04-sec. Q in lt. post. chest leads	9/10	90
Slur descending limb R V ₁	6/20	30
Slur descending limb R V ₂	2/20	10
V ₁ R/S \geq 1	12/20	60
V ₂ R/S \geq 1	19/20	95
Frontal QRS < 5 mm.	3/20	15
No abnormal Q waves	11/20	55
Q 2, 3, VF	6/20	30
Q 1, VL	2/20	10
Q 2, 3, VF, 1, VL	1/20	5
Upright T V ₁	10/20	50
Isoelectric T V ₁	6/20	30
Inverted T V ₁	4/20	20
Frontal T < 2 mm.	8/20	40
ST depression V ₁	4/20	20
ST depression V ₂	4/20	20
Frontal axis +70°	1/20	5
Frontal axis +15° to +45°	9/20	45
Frontal axis 0° to -15°	10/20	50

Table 3

Electrocardiographic Data in 100 Normal Controls

0.04-sec. R wave V_1	Unequivocal 0% borderline 4%
0.04-sec. R wave V_2	Unequivocal 3% borderline 10%
Slur descending limb R wave V_1	1%
Slur nadir S wave V_1	3%
Slur ascending limb S wave V_1	5%
Slur descending limb R wave V_2	3%
Slur nadir S wave V_2	2%
Slur ascending limb S wave V_2	0%
V_1 R/S ≥ 1	0%
V_2 R/S ≥ 1	12%
Upright T V_1	20%
Upright T V_2	95%
0.04-sec. R V_1 with frontal axis $+45^\circ$ to $+60^\circ$	75% (3/4 cases)
0.04-sec. R V_2 with frontal axis $+45$ to $+60^\circ$	39% (5/13 cases)
V_2 R/S ≥ 1 with frontal axis $+45$ to $+60^\circ$	58% (7/12 cases)

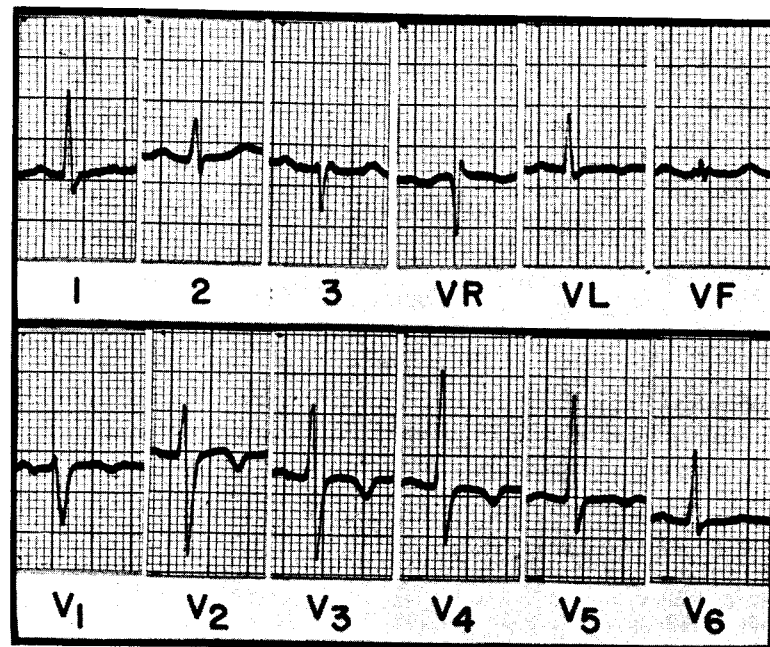


Figure 3

Case 6, table 1. Electrocardiogram before infarction (history of angina) for comparison with figure 4. Note absence of pathologic Q waves. Small R waves and inverted T waves appear in leads V_1 and V_2 .

to the left of the vertebral column (positions 1 through 15, fig. 2) but generally not as far as the angle of the scapula (positions 13 through 20). The Q area on the left side of the chest was relatively large. In normal subjects, posterior Q areas have been described on the right side of the chest with little or no extension to the left of the mid-

line.⁸ Such extensions when present were found to occupy relatively limited areas located high in the back.⁸

In the four autopsied subjects (table 1) the electrocardiographic designations of infarction were postero-diaphragmatic in two, postero-lateral-diaphragmatic in one, and strictly posterior in one. In each in-

stance there was an area of left ventricular infarction immediately below the atrioventricular sulcus adjacent to the interventricular septum. In the latter case (strictly posterior) the infarcted area was limited in extent and was associated with ventricular aneurysm. In the other three cases, the infarcted areas were more extensive and the electrocardiograms displayed diaphragmatic and lateral Q areas in addition to the increase in duration and height of the R wave in V_1 .

Lead V_1 was normal in five subjects. One had autopsy evidence consistent with acute

postero-diaphragmatic infarction and four had vectorcardiograms considered diagnostic of isolated strictly posterior infarction. The R/S ratios in lead V_2 were 1.4 to 2.5 in these five subjects. The T waves in lead V_2 were upright in all five. The R wave in lead V_2 was 0.04 second in four cases and 0.035 second in one (acute infarct, autopsied). There was a slur on the descending limb of the R wave in lead V_2 in two subjects. The frontal plane QRS electrical axes were $+30^\circ$ to $+40^\circ$ in three subjects and -5° to -30° in the other two.

The data in the normal group are summarized in table 3.

Discussion

The dorsal or infra-atrial portion of the left ventricle may be anatomically oriented posteriorly just to the left of the vertebral column (fig. 1). Infarction in this area, by causing loss of posteriorly directed electrical forces, can produce a recognizable anterior shift in the QRS loop of the vectorcardiogram (fig 1b).¹⁵⁻²⁰ In the electrocardiogram, there may be an accompanying increase in duration and amplitude of the R wave in lead V_1 .^{7-10, 12, 15} The T wave may become upright^{10, 12, 13} and, in the acute stage, the ST segment may be depressed.^{9, 10, 13} Thus, lead V_1 becomes the mirror image of an anterior infarction (fig. 1a)⁷ and the more familiar "infarct pattern" appears in posteriorly placed V leads^{7, 12} (fig. 1b).

Strictly posterior myocardial infarction is considered to be relatively uncommon.¹³ Its true incidence is difficult to assess since the electrocardiographic diagnosis is not routinely made. When posterior infarction occurs as an isolated lesion, pathologic Q waves do not appear in the standard electrocardiogram.^{8, 9} When the combination of either postero-diaphragmatic or postero-lateral infarction occurs, the extent of the infarcted area may be misjudged. Finally, signs of reinfarction may be overlooked in the electrocardiogram of a subject who experiences a strictly posterior infarct in the presence of a previous diaphragmatic or lateral infarct.

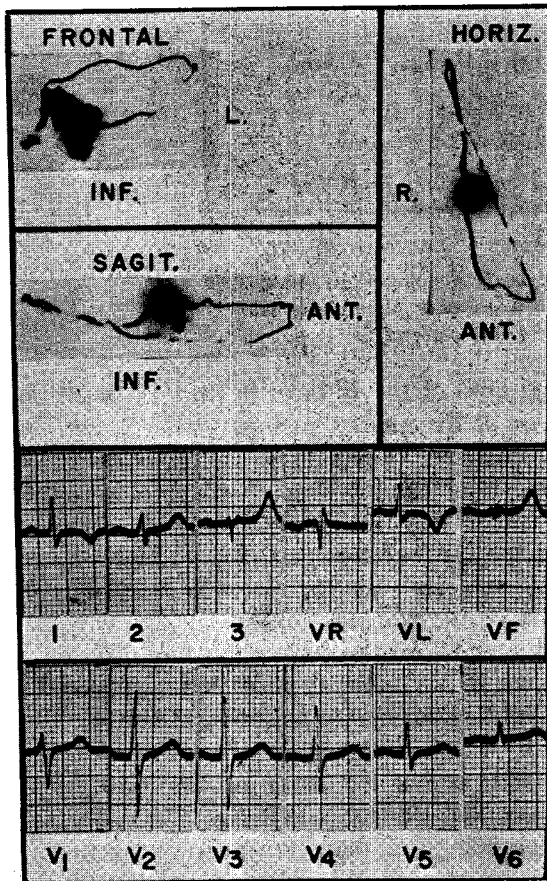


Figure 4

Case 6, table 1. Upper, vectorcardiogram after infarction illustrating the anterior QRS shift in the horizontal plane. Lower, Electrocardiogram after infarction for comparison with figure 3. Note absence of pathologic Q waves. Lead V_1 now manifests an R wave of 0.04 second with slurred descending limb. Right precordial leads display upright T waves and the R/S ratio in V_2 has increased to one.

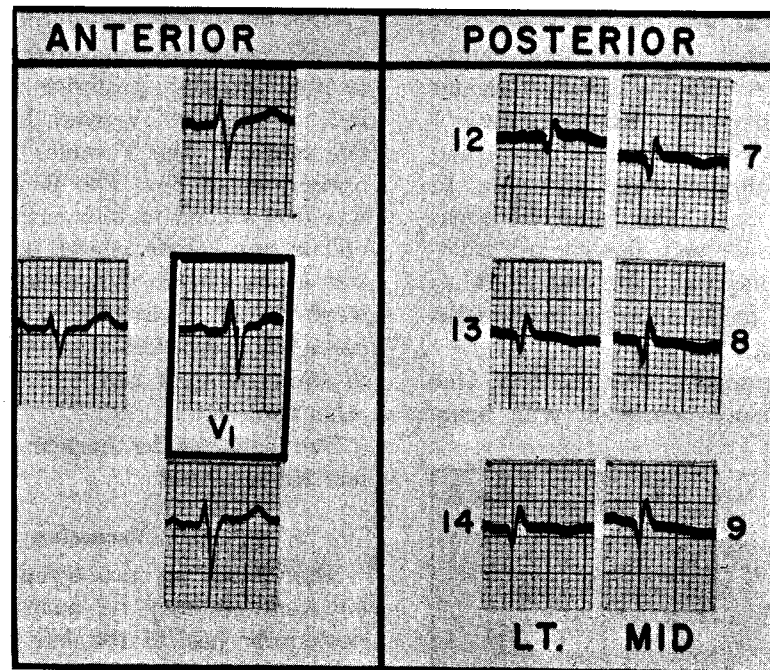


Figure 5

Case 6, table 1. Extra right anterior chest leads showing R waves of 0.04 second with slurred descending limbs. Extra posterior chest leads with Q area to the left of the midline. See figure 2 for lead placements.

The electrocardiographic diagnosis of strictly posterior infarction depends principally upon the detection of an abnormal anterior shift in the QRS (figs. 1b, 3, and 4). According to the data in this study (table 2), the abnormal anterior shift was most frequently manifested by 0.04-second R waves in leads V_1 (75 per cent) and V_2 (100 per cent) (figs. 3 through 5). Lead V_1 was the more dependable of the two, since R waves of 0.04-second in V_1 occurred in only four of the normal tracings (table 3). The anterior QRS displacement was further reflected by an R/S ratio of one or more in leads V_1 (60 per cent) and V_2 (95 per cent) (table 2, figs. 6 through 8). Again lead V_1 was the more dependable of the two since R/S ratios of this magnitude were not found in V_1 in any of the normal tracings (table 3). R waves of abnormal duration or amplitude in V_1 were particularly reliable signs when tracings before infarction were available for comparison (figs. 3, 4, 6, and 8).

A slur or notch occurred on the descend-

ing limb of the R wave in lead V_1 in 30 per cent of the infarct tracings (table 2, figs. 1b, 4, and 5). Others have called attention to this type of notching^{8,9} which appears to coincide with an abrupt change in direction of the QRS vector loop (fig. 4). In the normal subjects a similar slur was found in only one of the tracings (table 3). The presence of a notch on the descending limb of the R wave in V_1 might therefore be considered a helpful minor sign in posterior infarction.

R waves of 0.04 second were commonly found in one or more of the extra right precordial leads (table 2, figs. 2 and 5). The morphology of these R waves was generally similar to lead V_1 including slurring of the descending limb (fig. 5). Q waves of 0.04 second were commonly found in the extra left posterior chest leads^{8,12} between the spine and the scapula (figs. 2 and 5). These Q areas reflected the loss of posteriorly directed electrical forces and were diametrically opposite the right anterior chest leads where 0.04-second R waves were recorded (fig. 1b).

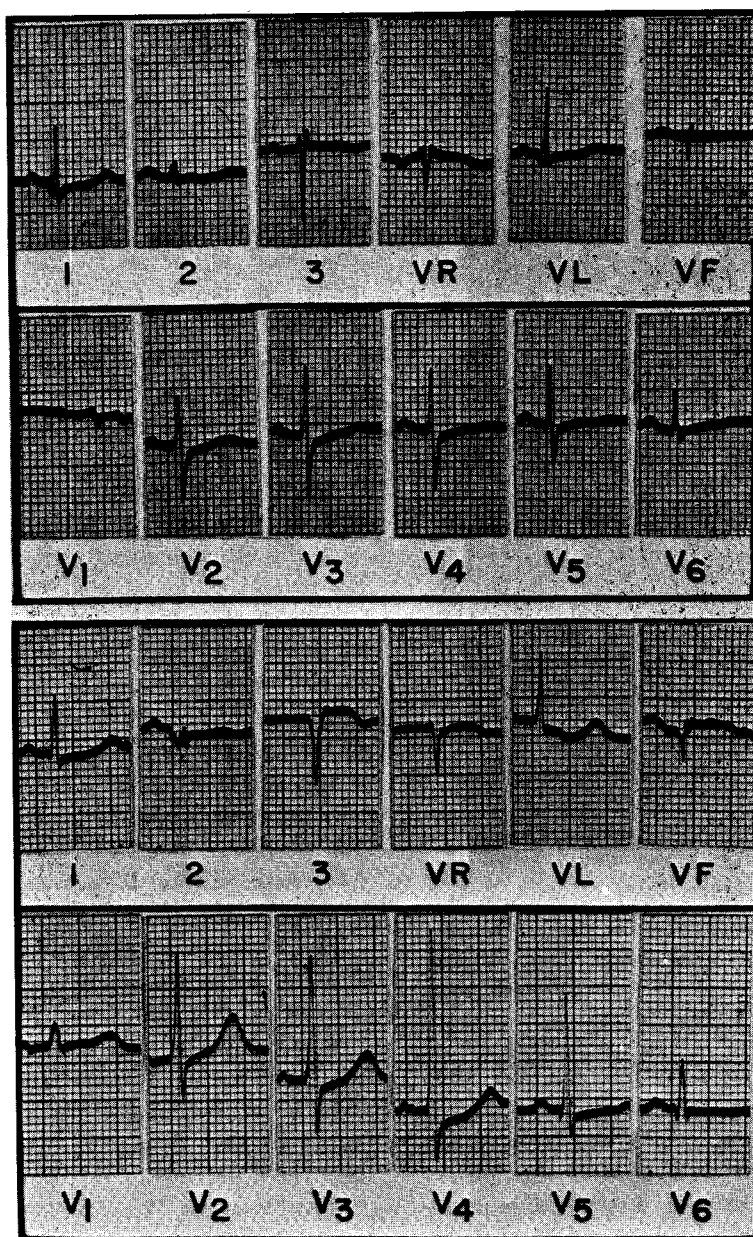


Figure 6

Case 19, table 1. Upper. Electrocardiogram before infarction for comparison with tracing below. Note absence of pathologic Q waves. Small R waves and shallow T waves appear in leads V_1 and V_2 . Lower. Electrocardiogram after infarction. Pathologic Q waves of diaphragmatic infarction are now present in leads II, III, and VF. In addition, leads V_1 and V_2 now manifest the anterior QRS shift of strictly posterior infarction. The R waves in these leads have become broad and tall and the T waves have increased in amplitude. See figure 7 for autopsy location of infarction.




Figure 7

Case 19, table 1. Autopsy specimen showing infarction of the left ventricle immediately below the left atrial attachment adjacent to the interventricular septum. See figure 6 for electrocardiograms.

The Q waves were recorded well to the left of the midline in contrast to normal subjects in which posterior Q areas have been found to lie on the right side of the chest with little or no extension beyond the midline.⁸ The extra chest leads were helpful in corroborating the information contained in lead V_1 but generally did not contain additional diagnostic information.

Consideration was given to the possibility that a decrease in amplitude of the limb lead QRS might accompany the anterior shift in electromotive force. Amplitudes of 5 mm. or less were considered abnormally small.¹ Only 15 per cent of the infarct tracings had frontal

plane QRS amplitudes of less than 5 mm. (table 2) although in two of the acute infarcts the limb lead QRS voltage decreased when compared with control tracings (figs. 3, 4, and 8).

Eleven of the infarct tracings contained no abnormal Q waves (table 2) and were believed to represent examples of isolated strictly posterior infarction. The most frequent associated abnormal Q area was diaphragmatic (six cases) (fig. 6). Lateral infarction coexisted in two instances and both lateral and diaphragmatic infarction coexisted in one instance (fig. 8). These observations indicate that although strictly posterior myocardial infarction can occur as an isolated lesion,^{11, 17, 18} it often occurs in association with diaphragmatic or lateral infarction.¹⁵⁻¹⁸

As the QRS electrical axis shifts leftward in the frontal plane, it also tends to shift posteriorly in the horizontal plane.²² The more leftward the limb lead axis, the less conspicuous are the R waves in leads V_1 and V_2 . It follows that broad or tall right precordial R waves assume greater diagnostic importance in the presence of leftward deviation of the QRS electrical axis. It is significant that the frontal plane electrical axes were between $+45^\circ$ and -15° in 95 per cent of the infarct tracings in this series.

The T wave is characteristically directed away from the area of infarction. In a strictly anterior infarct, the T wave in V_1 should be inverted (fig. 1a). In a strictly posterior infarct,^{10, 12, 13} this T wave should be upright (figs. 1a, 4, 6, and 8). The majority of cases (table 2) had T waves in V_1 that were upright (50 per cent) or isoelectric (30 per cent). However, T waves were upright in V_1 in 20 per cent of the normal tracings (table 3). Furthermore, it should be anticipated that the upright T waves of acute posterior infarction (fig. 8) might become isoelectric or inverted when the infarct heals. Despite these limitations, an anterior shift in the T wave is a valuable sign of strictly posterior infarction^{10, 12, 13} especially when tracings before infarction are available for comparison (figs. 3, 4, 6, and 8).

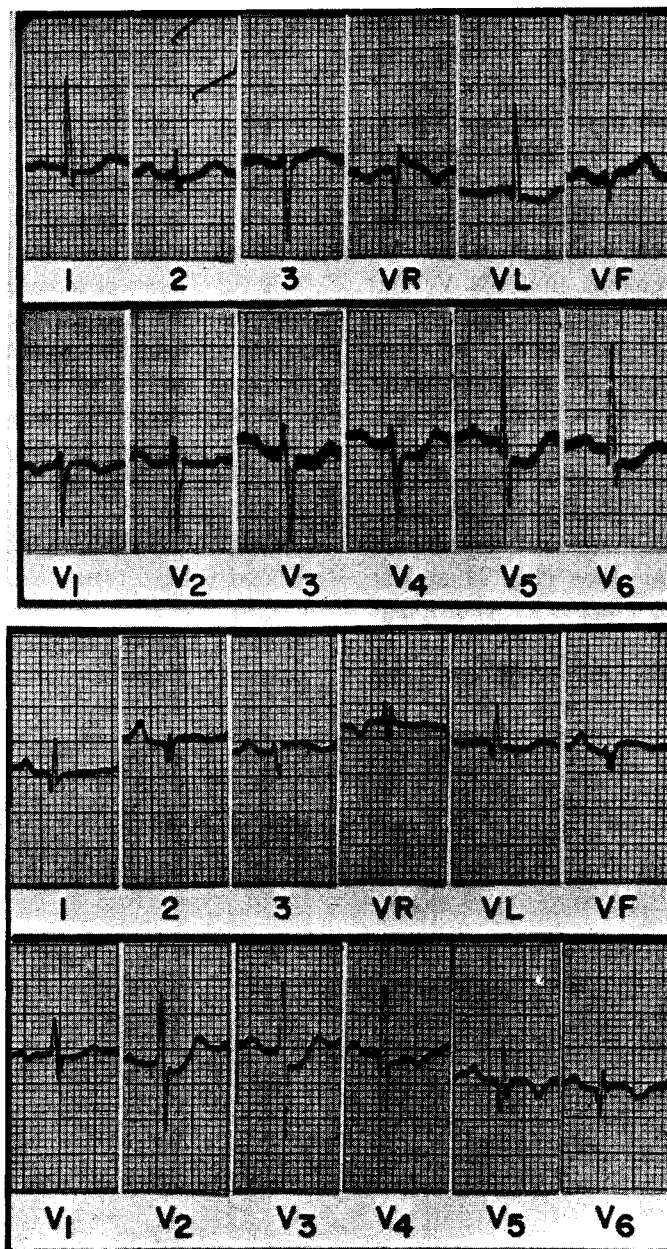


Figure 8

Case 3, table 1. Upper. Electrocardiogram before infarction for comparison with tracing below. Note absence of pathologic Q waves. Small R waves and inverted T waves appear in leads V_1 and V_2 . Lower. Electrocardiogram of acute infarct. Q waves in leads I, V_L , and V_{5-6} have increased in duration and a Q wave has appeared in lead II. In addition, there is a striking anterior shift in the QRS manifested by broad, tall R waves in the right pre-cordial leads. In leads V_1 and V_2 the ST segments are now depressed and the T waves upright. Patient autopsied.

A decrease in amplitude of the T waves in the limb leads has been described as an accompaniment of the anterior T shift.⁷ In this series (table 2) 40 per cent of the T waves in the limb leads were less than 2 mm., which was considered the lower limits of normal.¹

The ST segment typically deviates toward an area of acute myocardial infarction. Elevations of the ST segments in leads V₁ and V₂ are therefore found in acute anterior infarction (fig. 1a) and depressions in these leads can be anticipated in acute posterior infarction^{9, 10, 12} (figs. 1a and 8, table 2). Persistence of this acute shift in the ST segment is an electrocardiographic sign of ventricular aneurysm.⁹ One patient in this series manifested persistent ST-segment depressions in the right precordial leads (fig. 9) and at autopsy had an isolated posterior ventricular aneurysm.

Five patients in the infarct group (one

autopsied) had a normal lead V₁. In this group lead V₂ manifested the 0.04-second R waves and increased R/S ratios consistent with posterior infarction. However, the incidence of similar R and T-wave changes in the normal V₂ (table 3) limited the diagnostic usefulness of this lead. It may be significant that in all five of these patients the limb lead electrical axis was leftward (+40° to -30°). These observations, though limited, suggest that the diagnosis of posterior infarction might be suspected when V₂ includes the combination of broad tall R waves with slurred descending limbs, upright T waves, and ST-segment depressions in the presence of leftward deviation of the limb lead electrical axis.

Lead V₁ may manifest R waves of 0.04 second or R/S ratios equal to or greater than one in five other categories of electrocardiograms. Of these categories the normal child²³ poses no diagnostic problem. Complete right

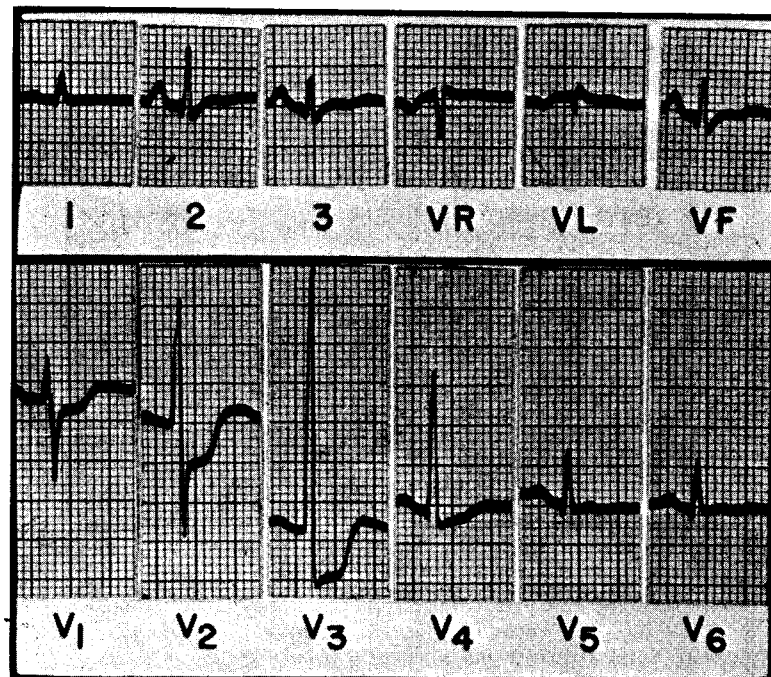


Figure 9

Case 2, table 1. Note in lead V₁ the 0.04-second R wave with slurred descending limb, the R/S ratio in V₂ greater than one, and the marked ST-segment depressions in V_{1,3}. At autopsy the patient had strictly posterior infarction (old) with posterior ventricular aneurysm.

bundle-branch block²⁴ and the Wolff-Parkinson-White syndrome with anteriorly directed delta wave,¹ while readily recognizable in themselves, may not permit the electrocardiographic diagnosis of coexisting posterior infarction. This is the only type of infarct QRS deformity in the electrocardiogram which is obscured by right bundle-branch block,²⁴ since the conduction defect is in itself associated with a broad R wave in V_1 . Disease states associated with right ventricular hypertrophy should be excluded by careful clinical evaluation.¹³ From the electrocardiographic point of view, upright T waves in lead V_1 ¹³ and leftward deviation of the limb lead electrical axis are exceptional in right ventricular hypertrophy but common in posterior infarction. Occasionally it may be difficult to distinguish a normal from an abnormal 0.04-second R wave in V_1 in the adult. In the normal tracings R waves of 0.04 second¹ in V_1 tended to occur with frontal plane axes greater than $+45^\circ$ (table 3). A rightward shift in the limb lead axis may normally be associated with a relatively anterior shift in the QRS analogous to the electrical axes of the child.^{9, 22, 23} It appears that the more vertical the electrical axis, the more likely is the normal occurrence of an R wave of 0.04 second in V_1 .

Summary

This study was undertaken in order to determine whether the standard scalar electrocardiogram contains sufficient information to permit the recognition of strictly posterior myocardial infarction. Sixteen patients were selected on the basis of vectorcardiographic evidence and four on the basis of autopsy evidence. One hundred normal adult electrocardiograms served as controls. The data indicate that strictly posterior infarction causes (1) R waves of 0.04 second in V_1 and in contiguous right anterior chest leads with upright T waves and, in the acute phase, ST-segment depressions, (2) Q waves of 0.04 second in an area posteriorly between the spine and the left scapula, (3) R/S ratios equal to or greater than one in V_1 and V_2 , (4)

slurring of the descending limb of the R wave in lead V_1 due to abrupt change in QRS direction, and (5) no pathologic Q waves in the standard 12 leads unless diaphragmatic or lateral infarction coexists. Extra chest leads derived from the right anterior and left posterior thorax serve principally to corroborate the diagnoses. R waves of 0.04 second or R/S ratios equal to or greater than one in lead V_1 were also found in the normal child, complete right bundle-branch block, the Wolff-Parkinson-White syndrome with an anteriorly directed delta wave, right ventricular hypertrophy, and an occasional normal adult especially with vertical frontal plane electrical axis. Attention to these differential diagnoses and to the foregoing manifestations of strictly posterior infarction facilitate its recognition by conventional scalar electrocardiography.

Acknowledgment

The vectorcardiograms were taken and interpreted in the laboratory of Dr. Hubert V. Pipberger. The author is most grateful to Dr. Pipberger for his interest and advice and for his critical review of the manuscript. The author further acknowledges Dr. Robert P. Grant, for his invaluable suggestions when the study was first begun.

References

1. LEPESCHKIN, E.: *Modern Electrocardiography*. Baltimore, The Williams & Wilkins Co., 1951, pp. 140, 351.
2. GOLDBERGER, E.: *Unipolar Lead Electrocardiography and Vectorcardiography*. Ed. 3. Philadelphia, Lea & Febiger, 1953.
3. BERNREITER, M.: *Electrocardiography*. Ed. 2. Philadelphia, J. B. Lippincott Company, 1963.
4. BARKER, J.: *The Unipolar Electrocardiogram*. New York, Appleton-Century-Crofts, Inc., 1952.
5. KATZ, L. N.: *Electrocardiography*. Philadelphia, Lea & Febiger, 1946.
6. DIMOND, E. G., SCHLESINGER, P., AND LUNA, R. L.: *Electrocardiography*. Kansas City, Corinth Press, 1961.
7. GRANT, R. P., AND ESTES, E. H.: *Spatial Vector Electrocardiography*. Philadelphia, The Blakiston Co., 1951, p. 117.
8. GRANT, R. P., AND MURRAY, R. H.: QRS complex deformity of myocardial infarction in the human subject. *Am. J. Med.* 17: 587, 1954.
9. MASSIE, E., AND WALSH, T. J.: *Clinical Vector-*

- cardiography and Electrocardiography. Chicago, The Year Book Publishers, Inc., 1960, pp. 313, 333.
10. MEYERS, G. B., KLEIN, H. A., AND HIRATZKA, T.: VI. Correlation of electrocardiographic and pathologic findings in posterolateral infarction. *Am. Heart J.* 38: 837, 1949.
 11. WALSH, T. J., TIONGSON, P. M., STODDARD, E. A., AND MASSIE, E.: The vectorcardiographic QRS \vec{E} -loop findings in inferoposterior myocardial infarction. *Am. Heart J.* 63: 516, 1962.
 12. TULLOCH, J. A.: The electrocardiographic features of high posterolateral myocardial infarction. *Brit. Heart J.* 14: 379, 1952.
 13. TRANCHESI, J., TEIXEIRA, V., EBAD, M., BOCALANDRO, I., BOCANEGRA, J., AND PILEGGI, F.: The vectorcardiogram in dorsal or posterior myocardial infarction. *Am. J. Cardiol.* 7: 505, 1961.
 14. LEVY, L., AND HYMAN, A. L.: Difficulties in the electrocardiographic diagnosis of myocardial infarction. *Am. Heart J.* 39: 243, 1950.
 15. ELEK, S. R., ALLENSTEIN, B. J., KORNBLUTH, A. W., GRIFFITH, G. C., AND LEVINSON, D. C.: The spatial vectorcardiogram in myocardial infarction typified by prominent R waves in leads aV_R and V₁. *Am. Heart J.* 47: 477, 1954.
 16. ROTHFELD, E. L., BERNSTEIN, A., WACHTEL, F. W., AND KARLEN, W. S.: The vectorcardiogram in direct posterior wall myocardial infarction. *Am. J. Cardiol.* 7: 496, 1961.
 17. WOLFF, L., MATHUR, K. S., AND RICHMAN, J. L.: The diagnosis of posterior myocardial infarction. *Am. Heart J.* 46: 21, 1953.
 18. SCHERLIS, L., AND GRISHMAN, A.: Spatial vectorcardiography: Myocardial infarction. *Am. Heart J.* 42: 24, 1951.
 19. GRISHMAN, A., SCHERLIS, L., AND LASSER, R.: Spatial vectorcardiography. *Am. J. Med.* 14: 184, 1953.
 20. SCHERLIS, L., LASSER, R. P., AND GRISHMAN, A.: Spatial vectorcardiography: The normal vectorcardiogram. *Am. Heart J.* 42: 235, 1951.
 21. PIPBERGER, H.: The normal orthogonal electrocardiogram and vectorcardiogram. *Circulation* 17: 1102, 1958.
 22. GRANT, R. P.: *Clinical Electrocardiography*. New York, McGraw-Hill, 1957, p. 51.
 23. NADAS, A.: *Pediatric Cardiology*. Philadelphia, W. B. Saunders, Company, 1963, p. 63.
 24. GRANT, R. P.: Mechanisms of QRS prolongation in man. *Am. J. Med.* 21: 534, 1956.