


*Unsuspected Neurologic Disease in
Aviation Personnel:
Survival Following Seizures in Flight*

JOHN H. SEIPEL, Ph.D., M.D., and ARTHUR E. WENTZ, M.D.



Unsuspected Neurologic Disease in Aviation Personnel: A. Survival Following Seizures in Flight—I

JOHN H. SEIPEL, PH.D., M.D., and ARTHUR E. WENTZ, M.D.

THE INCREASING USE of private and commercial air transportation combined with the steady increase in recreational aviation have inevitably increased the likelihood of pilot failure caused by medical disability simply because there are more pilots in the air more frequently. Thus, the problem of the early detection of disease likely to cause incapacity without warning has become serious.

Parallel to its research into the physiology of aging, the Georgetown Clinical Research Institute has examined a large number of applicants who had been denied certification at the regional level and who were referred in consultation to determine as precisely as possible their medical status prior to disposition of their

applications by higher authority. These airmen have been studied extensively, as is routine for applicants examined in the Institute; additional other studies have been performed in depth where indicated to clarify the status of their diseases and to give baselines for future comparison.

As members of the Institute and consultants to the Federal Aviation Agency in neurology, the authors have examined a large number of airmen who have neurological problems bearing on aviation medical certification. Many of these case histories dramatically illustrate important facets of neurological disease and its management; these histories also illustrate that much disease of the nervous system is being overlooked by Aviation Medical Examiners and other physicians who have had occasion to see these airmen. Since pre-existing neurological disease is particularly prone to cause sudden and catastrophic incapacity without warning, we are presenting a series of these histories as case reports to indicate the importance of the early and

Dr. Seipel is Senior Aviation Medical Examiner #4542-08-5, Chief, Neurology Branch, Georgetown Clinical Research Institute, AM-130, Federal Aviation Agency, Washington 25, D. C.

Dr. Wentz is Director, Georgetown Clinical Research Institute, AM-130, Federal Aviation Agency, Washington 25, D. C.

nations referred to the chief senses, such as unusual sounds, foul smells or tastes, unusual lights or scotomata, and sudden strangeness of familiar surroundings or its reverse. As patients will frequently *not* volunteer such information for fear they might be thought to be mentally deranged such points should be specifically and sympathetically questioned.

2. Sudden and abrupt loss of consciousness rather than the relatively slower "blacking-out" seen in syncope;

3. Evidence of self-injury, such as tongue biting, head injuries, and bruises and lacerations on the body;

4. Urinary or fecal incontinence;

5. Post-episodic confusion, generalized or focal motor weakness, headache, and tiredness; and

6. Evidence of convulsive movements or inappropriate activity as noted by persons who may have witnessed the episode.

Should one or more of the previous be positive, in particular those of aura, self-injury, incontinence, convulsive movements, and post-ictal symptoms, the patient can be safely presumed to have had a seizure, whether any evidence of abnormality is found on neurological examination or not. If the patient is an airman he *should be grounded immediately* until complete studies have been obtained; in the interests of his own safety and that of the public it is better to err on the side of conservatism rather than risk recurrence at a time when injury or fatality might result.

Despite a detailed history and examination, if the physician is not certain that the patient has had a seizure the patient can be told that all unexplained episodes of unconsciousness are potentially serious, that having occurred once they are likely to occur again *without warning* and *at any time*, and that he should not place himself in any situation, including driving a car and flying, where a recurrence might endanger himself or others. When a definite diagnosis has been established, the patient should be told he has seizures and his prognosis discussed. The word epilepsy, because of its adverse social and legal connotations, should not be mentioned under any circumstance. If directly questioned regarding epilepsy, unless he has a true idiopathic convulsive disorder the patient should be told he has a symptomatic convulsive disorder secondary to scar tissue, or whatever etiology, and that he does not have true "epilepsy."

It is not the purpose of this presentation to review the diagnosis and treatment of convulsive disorders; such information can be found in many standard textbooks. However, it should be noted that if the physician does not have complete familiarity in this field the patient should be referred to a neurologist for definitive studies and treatment if there is even a slight suspicion that a seizure may have occurred; had he been so referred, this patient might have been spared many years of uncertainty and distress.

Unsuspected Neurologic Disease in Aviation Personnel:

A. Survival Following Seizures in Flight—II

JOHN H. SEIPEL, PH.D., M.D., and ARTHUR E. WENTZ, M.D.

THE PROBLEM of the early detection of neurological disease in aviation personnel is serious because of the possibility of the sudden and catastrophic incapacity that may result from such disease. The problem of seizures while at the controls during flight is probably more common than might be suspected; the following case illustrates such incapacity and one relatively common etiology of seizures.

REPORT OF CASE

Case #AM-130-707:—This 34 year old white single applicant for a first class airman's certificate was referred to this facility for neurological consultation regarding an unexplained loss of consciousness. He was examined on June 18, 1962.

CHIEF COMPLAINT:—None.

INFORMANT:—The informant was the subject who was alert, cooperative, well oriented in all spheres, and apparently reliable.

His memory for the episode and its constellation of circumstances was only partially complete and was somewhat less so than would be expected considering its potential impact on his future. There was no attempt to withhold information apparent to the examiner.

PRESENT ILLNESS:—In 1946 the airman suffered a skull fracture in an automobile accident and was unconscious for 24 hours. The site of the fracture is unknown to him. On regaining consciousness he was amnesic for the episode; his memory cleared completely in several days. He was hospitalized for several months and was symptom-free for the entire period. Records from the hospital at which he was treated were unavailable. He had brief orthostatic hypotension for 1-2 years following the skull fracture and subsequently worked as a steeple jack for 4-5 years without incident.

The subject had generally been eating and sleeping very little for some months prior to his episode; the previous day being in no way different from the previous many. He slept several hours during that day and remained awake continuously during the succeeding time, flying as co-pilot on a night flight leaving Ogden, Utah on December 7, 1961. The flight was delayed in Cheyenne and again in Denver. On the approach and final run of the trip's termination in Topeka, Kansas, he noted nothing unusual until he regained consciousness on the landing roll; according to his pilot he had been out for approximately 20 minutes. There

was no aura of any sort; he had been functioning well. As related by the pilot, he was sitting up looking straight ahead, made no response when spoken to, slumped to the right side of his seat, and struck his head injuring his nose. He made no sound or noise; a slight jerking motion of his left side was seen. His pilot was unable to assist him and neither attempted to awaken him or to check his condition as he had to land the plane alone. There was no incontinence; the applicant bit the left side of his tongue during the episode. On awakening he felt "hazy" but was neither tired, "washed out," nor weak, and had no headache. He began the usual checks; his pilot took over the paperwork because the airman's writing was illegible. He was able to converse coherently. The next day he flew back with the airline chief pilot and did well.

He was hospitalized later in December for a complete neurological evaluation. Following its completion, he was placed on Dilantin therapy, 100 milligrams three times a day, and has remained seizure-free on this medication. He has had no prior or subsequent similar episodes and no history of seizures as a child.

PAST HISTORY:—Non-contributory.

GENERAL PHYSICAL EXAMINATION:—Within normal limits.

NEUROLOGICAL EXAMINATION:—On neurological examination he was a slim, well-developed, well-nourished, right-handed white male in no distress. The neurological examination was entirely unremarkable except for air conduction hearing equaling bone conduction hearing on the left, two-point discrimination of 9 millimeters on the right and 17 millimeters on the left, and the minor memory deficit previously noted.

LABORATORY:

URINALYSIS: Normal

BLOOD: Normal

CHEMISTRY: Serum Cholesterol—400 mg. per cent. Fasting Blood Sugar—112 mg. per cent.

ELECTROCARDIOGRAM: Normal

DOUBLE MASTER: Normal

VISION: Normal

HEARING: Normal in left ear. 35 db. loss @ 2 KC. in right ear.

RADIOLOGICAL:

Skull:—Within normal limits with no evidence of old fracture. The films from his neurological work-up were available and were reviewed.

Carotid Arteriograms:—Films were late phase and showed little detail of the major vessels. There was good filling to the inner table on the left. No injection on the right was performed.

Pneumoencephalogram:—Films were excellent (Figure 1).

There was no cortical air and the ventricles were well outlined. In all projections the right ventricle was symmetrically larger than the left. No shift was seen.

ELECTROENCEPHALOGRAPHY:—A fairly adequate tracing

Dr. Seipel is a Senior Aviation Medical Examiner #4542-08-5 and Chief, Neurology Branch, Georgetown Clinical Research Institute, AM-130, Federal Aviation Agency, Washington, D. C.

Dr. Wentz is Director, Georgetown Clinical Research Institute, AM-130, Federal Aviation Agency, Washington, D. C.

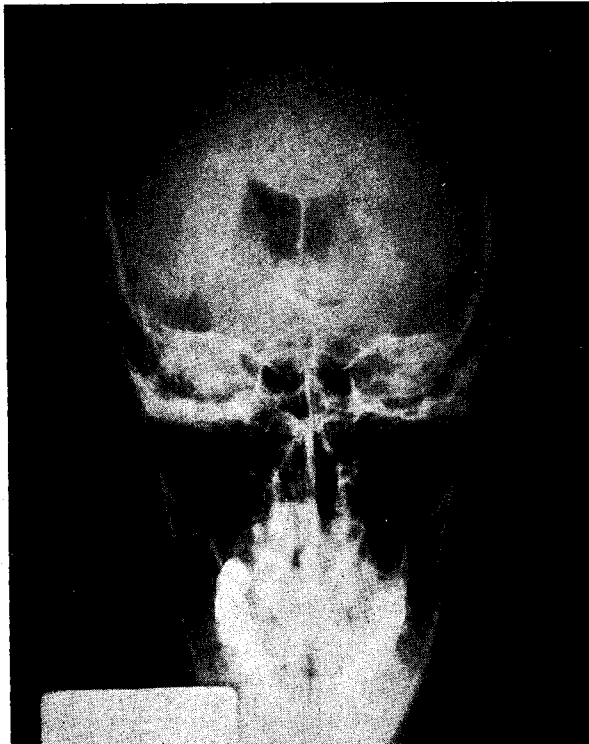


Fig. 1. Pneumoencephalogram showing slight right ventricular enlargement.

was obtained despite much movement artifact. The basic alpha rhythm was 10 per second; the record was poorly organized in all leads with evidence of diffuse dysrhythmia. An asymmetry of amplitude was noted with higher voltage activity present on the left in all leads; slowing to 4 per second was seen frequently on the left; frequent spikes were present in the left temporal leads and occasionally in the right temporal leads. High voltage bursts of irregular slow activity were occasionally seen in the left in all leads but were more marked in the temporal leads. Hyperventilation produced a further disorganization in all leads, particularly on the right, with build-up of high voltage activity and increased spiking bilaterally; 2 per second slowing was also apparent in all leads. The record was interpreted to show generalized abnormality compatible with a convulsive disorder and generalized cerebral atrophy more marked on the right.

IMPRESSION:—It was the impression of the examiner that this airman had suffered a grand mal seizure having a right cortical focal component; the underlying etiologic pathology was most probably diffuse cortical and subcortical atrophy and scarring secondary to the cerebral trauma sustained during and after the 1946 auto accident.

SUBSEQUENT COURSE:—The airman was subsequently denied certification by the Civil Air Surgeon's Medical Review Board; he then appealed to the Civil Aeronautics Board.

As he was unable to present expert medical testimony to indicate a diagnosis other than seizure his appeal was dismissed.

Since the neurologist he had most recently consulted indicated that the likelihood of another seizure was remote, it was explained to the airman that he could present his case in appeal to the Administrator's Medical Advisory Panel for exemption to the regulations; he was unaware of this possibility.

COMMENTS

In this case the history of abrupt loss of consciousness, the observed jerking of the left side, the tongue biting, and the postictal partial incapacity were diag-

nostic of seizure; the electroencephalogram supported the diagnosis and indicated a generalized cerebral abnormality. The subsequent pneumoencephalogram gave evidence of cerebral atrophy; and the past history gave a presumptive etiology.

Since the airman was actually in control of the plane when his seizure occurred it was fortunate that his pilot was able to assume control before an accident could occur. Had the episode taken place during landing a short while later the outcome might have been entirely different.

He was quickly and adequately studied; anticonvulsant therapy was promptly instituted. The medication and a change in his living habits to include sufficient sleep and food have resulted in his remaining seizure-free to the present.

DISCUSSION

In the absence of a history of infantile or childhood seizures, seizures of late onset occurring for the first time after the adolescent age range (in which idiopathic convulsive disorders are likely to occur) must be considered as pathognomonic of brain tumor because of the potential seriousness of this disease; such patients must be studied promptly and intensively to rule out this possibility and to determine the correct etiology where possible. Anticonvulsants should be started as soon as it has been determined that a seizure has occurred; their use will not interfere with the subsequent studies. This case history illustrates excellently such an evaluation and demonstrates a frequent pathologic etiology for seizures.

Most commonly no etiology will be found following a thorough study; space-occupying lesions frequently are initially sufficiently small that no observable abnormality can be seen on arteriography or pneumoencephalography. With time the expansion of the lesion continues and localizing neurological changes will develop; eventually, sufficient evidence can be amassed to enable surgical exploration. For this reason these patients should be carefully followed to permit definitive therapy as early as possible.

A frequent etiology of seizures is the intemperate use of alcohol, the so-called "alkalepsy." Since patients will rarely admit alcoholism and may exhibit few or none of the obvious findings of the disease, the physician is faced with the usual problem of suspicion but no proof. Discussion of the patient's habits with his family and associates is often helpful; the physician should be careful not to give offense by suggesting his suspicions and should mention the subject only as a part of his general inquiry into the patient's background.

As illustrated by the preceding case, a not infrequent finding is cortical and subcortical atrophy. Such pathology can arise from many causes such as trauma, vascular impairment, exposure to toxins, and sometimes apparently without determinable etiology. It is not certain at present whether atrophy, per se, can give rise to seizures or if the atrophy reflects underlying pathology, such as scarring, which gives rise to the seizures; in most cases the observed atrophy appears to be a part of the general brain reaction to insult of

one form or another. In the preceding case the electroencephalogram indicated that the airman suffered diffuse cortical traumatic damage with subsequent scarring and atrophy; the focal component of his seizure and the more apparent atrophy of the right cortex indicated that damage on this side was more marked than on the left.

Even should a plausible etiology be determined in a particular patient it should be emphasized that brain tumors can occur in alcoholics and persons who have suffered previous neurological disease. While all seizure patients should be followed at frequent intervals to rule out this remote possibility the major reason for close supervision is that the physician is thus made available for counseling and support. The patient who is suffering from a convulsive disorder is faced with an often shattering problem of reaching an understanding of his disease and its ramifications which often require far-reaching readjustments in his way of life.

A further point illustrated by this case is Federal Aviation Agency practice in cases in which medical certification is questioned. After denial at the Regional level the applicant has the right to request review by the Civil Air Surgeon's Medical Review Board. This Board of Agency consultants will then review the medical evidence and request further information where nec-

essary; the airman is given the opportunity of examination at the Georgetown Clinical Research Institute at no expense to him other than his transportation to Washington, food, and lodging. If, in the Board's opinion, the cause for denial is not supported by the evidence or if there is no standard that would preclude the safe exercise of privileges by the airman, certification is issued. If again denied, the airman has two alternatives; he can appeal to the Administrator for an exemption from the regulations or he can appeal directly to the Civil Aeronautics Board. Since the Medical Review Board and the Civil Aeronautics Board are bound by the regulations regarding certification, if a non-certifiable medical diagnosis has been established, certification cannot be granted by either body. The only group empowered to recommend to the Administrator that an exemption to the regulations be granted is the Administrator's Medical Advisory Panel. This panel is composed of outstanding senior consultants in the various specialties chosen from the entire country who consider each case individually. If, in their opinion, the airman's disease is stable and he can safely exercise the privileges of his certificate without danger to himself or to the public, an exemption may be granted by the Administrator and certification may be issued.

